Scandinavian Journal of Infectious Diseases, 2012; Early Online: 1–5

ORIGINAL ARTICLE

Computed tomography scan in supine and prone positions: An alternative method to detect intramural gas in emphysematous cystitis and to evaluate efficacy after adjuvant continuous intravesical irrigation treatment

JEFF R. CORTÉS-GONZÁLEZ[1], GERARDO E. ORTIZ-LARA[1], MATÍAS SALINAS[2], FERNANDO HERNÁNDEZ-GALVÁN[1] & LAURO S. GÓMEZ-GUERRA[1]

From the [1]Urology Service, and [2]Radiodiagnostics Service, "Dr. José E. González" University Hospital, Universidad Autónoma de Nuevo León, Monterrey, Nuevo León, Mexico

Abstract

Objective: To evaluate the efficacy of continuous intravesical irrigation with saline plus amikacin as adjuvant therapy and to evaluate the computed tomography (CT) scan in supine and prone positions (CystoCT scan) as an alternative diagnostic and evaluation method of intramural gas in emphysematous cystitis (EC) before and after treatment. *Methods:* Consecutive patients with a diagnosis of EC who were hospitalized between March 2006 and January 2011 were investigated. The diagnosis was made by CystoCT scan. Treatment consisted of intravenous antibiotics, control of concomitant diseases, and placement of a 3-way urinary catheter for continuous irrigation of 500 mg of amikacin diluted in 1 l of saline given on days 0, 3, and 7. Treatment was considered successful when there was an absence of gas in the bladder wall, the urine culture was negative, there was clinical improvement, and there was an absence of toxicity. *Results:* Eleven patients were hospitalized with a diagnosis of EC during the study period. Four were excluded from the study, 2 due to the lack of confirmation of the diagnosis with the CystoCT scan. Treatment was successful in all patients; for 6 (86%) this was achieved in 3 days and for 1 (14%) in 7 days. No toxicity was reported. *Conclusions:* Continuous intravesical irrigation with saline plus amikacin as adjuvant treatment of EC is an inexpensive, effective, and safe tool that might help conventional treatment and provide a rapid recovery. The CystoCT scan is an alternative method to diagnose and evaluate intramural gas in EC patients. These findings should be challenged in a randomized, multi-centre, placebo-controlled clinical trial.

Keywords: *Cystitis, amikacin, urinary tract infections, glycosuria, CT scan*

Introduction

Emphysematous cystitis (EC) is a rare but potentially fatal urinary tract infection (UTI). It is characterized by the presence of gas within the bladder wall secondary to a gas-forming bacterial infection that produces fermentation of glucose and protein in urine [1–3]. Another theory suggests an inadequate host response secondary to vascular and catabolic tissue deterioration that predisposes to the production of gas in tissue [2]. The diagnosis should be accurate and treatment must be given immediately and be aggressive to avoid fatal consequences [2–4].

Treatment usually consists of control of concomitant diseases that cause immunosuppression, administration of parenteral combined broad-spectrum antibiotics (a second- or third-generation cephalosporin and an aminoglycoside), and placement of a transurethral catheter until clinical improvement is observed. The average hospital stay is 7–10 days; nevertheless it can be more than 1 month [3,4].

The aims of this study were to evaluate the efficacy of continuous intravesical irrigation with saline plus amikacin as adjuvant therapy and the CystoCT scan as an alternative diagnostic and evaluation method after the treatment of EC.

Correspondence: J. R. Cortés-González, Servicio de Urología, Hospital Universitario "Dr. José E. González" UANL, Av. Madero y Gonzalitos s/n Colonia Mitras Centro, Monterrey, Nuevo León, 64460, Mexico. Tel: +52 81 83331713. Fax: +52 81 83331713. E-mail: jrcor77@yahoo.com

(Received 23 July 2012; accepted 27 September 2012)

ISSN 0036-5548 print/ISSN 1651-1980 online © 2012 Informa Healthcare
DOI: 10.3109/00365548.2012.737018

Patients and methods

Patients

Consecutive patients with a diagnosis of EC hospitalized between March 2006 and January 2011 were included in this study. Contraindications to intravesical irrigation treatment were: intravesical gas pattern changes after CystoCT scan, the presence of bladder stones, vesico-rectal or entero-vesical fistulae, bladder intraluminal gas following recent urinary instrumentation, a positive fungus culture, and pregnancy.

Diagnosis and laboratory tests

The diagnosis was obtained by CystoCT scan, which consists of an intravesical and intravenous contrast-enhanced CT scan in the prone and supine positions. In the case of renal impairment, only intravesical contrast was given. The intravenous and intravesical contrast medium was ioversol 51% (Optiray™ 240). Intravesical administration was with 20 ml of ioversol 51% diluted in 1 l of saline given slowly through the 3-way urinary catheter. In order to obtain better images of the bladder wall, the slices were made every 2.5 mm with reconstructed images every 1.2 mm. Blood (complete blood count, chemistry, serum electrolytes, and liver enzymes) and urine (urinalysis and urine culture) samples were obtained. Both laboratory work-up and the CystoCT scan were carried out on days 0, 3, and 7 (the last in case of persistent disease) to evaluate persistence of intramural gas. Cystometry was performed during the hospital stay. In the case of abnormal results, the patients were sent for further urodynamic testing once the infection was resolved.

Treatment

Ceftriaxone 1 g intravenous (IV) twice daily plus amikacin 1 g IV once daily were administered as empirical therapy in all cases (with adjustment in the case of renal impairment). A 3-way transurethral catheter was placed to start continuous intravesical irrigation with saline plus amikacin (500 mg/l during and every 6 h) for 3 days.

Treatment was considered successful when the following criteria were met: no gas in the bladder wall demonstrated by a control CystoCT, negative urinary culture, clinical improvement, and laboratory tests within the normal range, demonstrating a lack of toxicity or other adverse effects.

Statistical analysis

The statistical program MedCalc version 11.1 was used. The count and frequency analysis was performed using Fisher's exact test; when variables were normally distributed (confirmed by the Kolmogorov–Smirnov test), the Student's paired *t*-test was preferred and when not, the Wilcoxon test was performed. *p*-Values of <0.05 were considered statistically significant. The study was submitted to and accepted by the ethics committee of our institution. All patients provided written informed consent. A patient previously reported in the literature was included in this series [1].

Results

Eleven patients were hospitalized with a diagnosis of EC during the study period. Two were excluded from the study: 1 had a positive urine culture for Candida tropicalis and the other had bladder stones. A further 2 were excluded due to the lack of confirmation of the diagnosis with the CystoCT scan (intravesical gas pattern distribution differed after change to prone position). The remaining 7 patients were given continuous intravesical irrigation. Their mean age was 59 y (standard deviation 10 y). Five patients (71%) were women, 6 (86%) had diabetes, and 4 (57%) had bladder outlet dysfunction. In the emergency department 2 patients (29%) referred to pneumaturia, 4 (57%) to abdominal pain, and 3 (43%) to fever. Other uncommon signs and symptoms were dysuria, flank pain, and haematuria. Urine culture was positive for Escherichia coli in 4 patients (57%), 2 (29%) had Enterobacter cloacae, and 1 (14%) had Streptococcus sp.

Mean serum glucose, glycosuria, and leukocyte counts improved clinically and this was statistically significant after 3 days, as shown in Table I. No toxicity was observed.

Treatment was successful for all patients – within 3 days for 6 (86%) patients and after 7 days for 1 (14%). Figure 1 shows the changes observed from the start of treatment to 3 days. Further follow-up was performed irregularly over the following year and some patients were lost to follow-up after resolution of the UTI. No deterioration in the creatinine levels was observed in those patients ($n = 4$) during their visits.

Discussion

EC occurs predominantly in women with diabetes mellitus [2]. Risk factors described in the literature include: neurogenic bladder, intermittent catheterization, chronic and/or repeated urinary tract infections, urinary stasis, bladder diverticulae, states of immunosuppression, bacteraemia, corticosteroid use and broad-spectrum antibiotics, the presence of haematological malignancies, and lupus [1–3]. The most

Table I. Relevant laboratory test results on admission and after 3 days of treatment.

Result	Admission Mean (SD)	Day 3 Mean (SD)	*p*-Value
Glucose (mg/dl)	368 (195)	118 (27)	0.02
Serum creatinine (mg/l)	2.07 (1.86)	2.15 (2.60)	0.68
WBC/mm^3	11,648 (3392)	8641 (2830)	<0.001
Platelets/mm^3	200,685 (108,068)	226,428 (117,150)	0.65
Glycosuria, *n* (%)	5 (71)	0 (0)	0.02
Proteinuria, *n* (%)	6 (86)	2 (29)	0.10

SD, standard deviation; WBC, white blood cell count.

common aetiological agent is Escherichia coli; however, other bacteria (Klebsiella pneumoniae, Proteus mirabilis, Staphylococcus aureus, Enterobacter aerogenes, Streptococcus spp., Nocardia, and Clostridium perfringens) and fungi (Candida albicans and Candida tropicalis) have been described [1–4]. Since its first description in 1888 by Eisenlohr [5] about 219 cases have been reported (references not shown).

One of the biggest challenges is to rule out illnesses that allow the collection of air within the bladder resembling the image of gas in the bladder wall. This may apply to other conditions where gas can be introduced, i.e., catheterization, introduction of intravesical contrast, and continuous intravesical irrigation. We minimized this effect by alternately placing the patient in the supine and then in the prone decubitus position. In this way we corroborated that the gas in the bladder wall remained in the same place after the position change. We complemented this with the double application of contrast media (intravenous and intravesical, when no contraindications were present), which provided a better definition of the bladder wall (mucosa and muscle) in order to avoid false-positives and discard multiple and potential differential diagnoses.

The use of CT in the diagnosis of EC is increasing. The diagnosis is usually an unexpected finding since symptoms are vague and pneumaturia is not always present. The most specific clinical sign is the presence of gas in the urinary tract. In this series only 2 patients (29%) had pneumaturia. Importantly, the

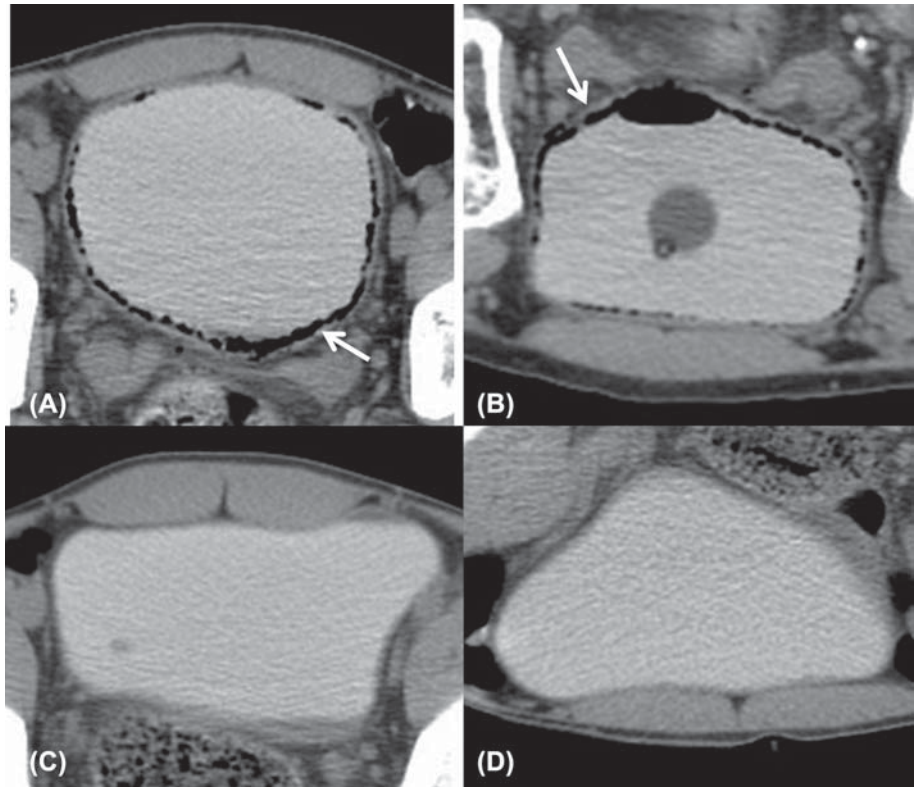

Figure 1. CystoCT scan showing persistent intraluminal gas despite a change of position (white arrows) in (A) and (B). (C) and (D) show satisfactory evolution in the same patient in the supine and prone positions after 3 days of treatment.

diagnosis was confirmed by the CystoCT scan and 2 patients were excluded from being given intravesical therapy since a change in the intravesical gas pattern and absence of intramural gas was observed, making this imaging technique an interesting and alternative tool to intramural gas detection. However due to the lack of a reference control procedure, caution must be taken when considering performing a CystoCT scan universally beyond the experimental setting. Nevertheless, to our knowledge this is the first study to relate the use of this approach in the diagnosis and evaluation of EC after intravesical treatment.

EC is a rare disease, making it difficult to conduct scientific studies with a larger number of subjects. As mentioned above, to date about 219 cases have been reported and all in the form of case reports. The largest series are those of Mills with 12 cases, Bailey with 19 cases, and Bjurlin et al. more recently with 15 [6–8]. With 9 cases, the present study is the 4th largest series and the first to prospectively evaluate an adjuvant treatment and a new diagnostic method.

The use of intravesical antibiotics is not new [9–14]. It has been reported that intravesical administration may have advantages over oral therapy, since the drug is given directly at the site of infection; the impermeability of the bladder minimizes possible systemic effects [14]. However, in patients with previous ileal augmentation cystoplasty, absorption could be higher, as reported by Krege et al. in a rabbit model, where the absorption of ofloxacin was greater [11]. Our group is the first to report the use of intravesical amikacin in a continuous irrigation mode as treatment for a lower UTI.

Wan et al. described empirical instillation of gentamicin 480 mg diluted in 1 l of saline by intermittent catheterization as prophylaxis and treatment of bacilluria in adult patients with spinal cord injuries [14]. Hajjar et al. first published the continuous administration of an intravesical antibiotic through a 3-way transurethral catheter. They administered 1 g of vancomycin diluted in 1 l 0.9% NaCl solution at 42 ml/h every 24 h for 5 days as treatment for lower UTIs caused by methicillin-resistant Staphylococcus aureus [10]. Waites et al. published a study that evaluated 3 methods of bladder irrigation to treat bacteriuria in individuals with neurogenic bladder [13]. Irrigation was performed by intermittent catheterization, 2 times daily for 8 weeks, and 3 groups were compared. The first was irrigated with saline, the second with acetic acid, and the third with neomycin–polymyxin. They found no benefit in eradicating bacteriuria in any group. Defoor et al. also published a study that evaluated the safety of bladder irrigation with gentamicin in complex urological cases. In children, they administered 14 mg of gentamicin in 30 ml of saline through catheterization once or twice a day [9]. Salehipour et al. described the use of intravesical amikacin, which was applied trans-operatively as prophylaxis for UTI after renal transplantation [12]. In all the previously mentioned studies, except the one comparing 3 different types of bladder irrigation, very good results were obtained and none reported significant systemic absorption of drugs, although it was shown that there is a greater absorption in the urothelium of an infected bladder due to the local inflammatory process [14]. This is consistent with the findings in the present study in which none of our patients presented toxicity. However, there are still doubts about the pharmacodynamics and pharmacokinetics of intravesically administered antibiotics, i.e., obtaining the optimal dose. Future studies could focus on this and other issues. The median hospital stay was 3 days compared to ≥ 6 described in larger series with conventional treatment [6–8].

The ability of E. coli to ferment glucose producing CO_2 in vitro has been demonstrated and it is also known that the amount of gas in vivo necessary to produce EC is minimal. Four of our patients presented bladder outlet dysfunction, a neurogenic type in 3 cases and obstructive type in 1, probably due to myogenic dysfunction. All cases had large residual urine. We believe that urinary stasis strongly influences the development of EC, allowing time for the gas to accumulate and for an increase in its production. On the other hand, this would explain only those cases in which glycosuria was present; however, we had 2 patients without glycosuria, and of these, 1 had proteinuria, which reinforces the theory that proteins are also a substrate for fermentation. Proteinuria was present in 6 of 7 patients. Only 1 patient showed the presence of gas without any obvious cause.

Among the weaknesses of this study is the sample size and that the study was not randomized and placebo-controlled. However, as mentioned above, EC is a very rare disease which makes it difficult to include patients in a protocol. Another difficulty in this study is to understand the cost-effectiveness and the radiation exposure of performing the CystoCT scan two or three times, beyond the experimental approach.

In conclusion, the CystoCT scan technique is an alternative method in the diagnosis of intramural gas in EC patients and in the evaluation of the disease after intravesical treatment. Continuous intravesical irrigation with saline plus amikacin as adjuvant treatment of EC is an inexpensive, effective, safe tool that in conjunction with conventional treatment might lead to a rapid recovery, reducing a usually prolonged hospital stay. However, with the lack of a control group, these results should be ratified in a randomized, placebo-controlled, multi-centre study.

Acknowledgements

This study was supported by funds from the urology service, University Hospital "Dr. José E. González" UANL.

Declaration of interest: No conflict of interest to declare.

References

[1] Cortes Gonzalez JR, Ortiz Lara GE, Arratia Maqueo JA, Gomez Guerra LS. [Continuous bladder irrigation with amikacin as adjuvant treatment for emphysematous cystitis]. Arch Esp Urol 2007;60:1218–20.

[2] Thomas AA, Lane BR, Thomas AZ, Remer EM, Campbell SC, Shoskes DA. Emphysematous cystitis: a review of 135 cases. BJU Int 2007;100:17–20.

[3] Vásquez-Lastra C A-AA, Cisneros-Madrid B. Cistitis enfisematosa: reporte de un caso y revisión de la literatura. Rev Mex Urol 2004;64:312–9.

[4] Grupper M, Kravtsov A, Potasman I. Emphysematous cystitis: illustrative case report and review of the literature. Medicine (Baltimore) 2007;86:47–53.

[5] Eisenlohr W. Das interstitelle vagina, darm und harnblasenemphysem zurückfürt auf gasentwickelnde bakterien. Beitr Path Anat Allg Path 1888;3:101.

[6] Bailey H. Cystitis emphysematosa: 19 cases with intraluminal and interstitial collections of gas. Am J Roentgenol Radium Ther Nucl Med; 196186:850–62.

[7] Mills RG. Cystitis emphysematosa: report of series of cases in women. JAMA 1930;94:321–6.

[8] Bjurlin MA, Hurley SD, Kim DY, Cohn MR, Jordan MD, Kim R, et al. Clinical outcomes of nonoperative management in emphysematous urinary tract infections. Urology 2012;79:1281–5.

[9] Defoor W, Ferguson D, Mashni S, Creelman L, Reeves D, Minevich E, et al. Safety of gentamicin bladder irrigations in complex urological cases. J Urol 2006;175:1861–4.

[10] Hajjar RR, Philpot C, Morley JE. Continuous bladder irrigation with vancomycin for the treatment of methicillin-resistant Staphylococcus aureus. J Am Geriatr Soc 1996;44:886–7.

[11] Krege S, Kinzig-Schippers M, Sorgel F, Baschek R, Michel MC, Rubben H. Absorption of intravesically applied drugs: comparison of normal and ileal augmented rabbit bladder. J Urol 2004;172:2045–50.

[12] Salehipour M, Salahi H, Fathikalajahi A, Mohammadian R, Emadmarvasti V, Bahador A, et al. Is perioperative intravesically applied antibiotic solution effective in the prophylaxis of urinary tract infections after renal transplantation? Urol Int 2010;85:66–9.

[13] Waites KB, Canupp KC, Roper JF, Camp SM, Chen Y. Evaluation of 3 methods of bladder irrigation to treat bacteriuria in persons with neurogenic bladder. J Spinal Cord Med 2006;29:217–26.

[14] Wan J, Kozminski M, Wang SC, Faerber GJ, McGuire EJ, Bloom DA, et al. Intravesical instillation of gentamicin sulfate: in vitro, rat, canine, and human studies. Urology 1994;43:531–6.